

# Palmar and Plantar Hyperhidrosis: Best Practice Recommendations and Special Considerations

Dee Anna Glaser, MD; Adelaide A. Hebert, MD; David M. Pariser, MD; Nowell Solish, MD

*When topical therapy and tap water iontophoresis (TWI) fail, are unavailable, or are deemed unsatisfactory by patients with palmar or plantar hyperhidrosis (HH), the next logical treatment option is botulinum toxin type A (BTX-A). Skill and precision are required to treat palmar and plantar HH because of the dense innervation in the palms and soles. This article describes best practice techniques for BTX-A (Botox®), including suggested dilution and syringe selection, injection technique, dose and injection grids, and anesthesia recommendations. In addition, general BTX-A background and special considerations for treating palmar and plantar HH are provided. Insurance reimbursement for treating HH with BTX-A can be challenging; navigating the insurance reimbursement process will be discussed.*

*Cutis. 2007;79(suppl 5):18-28.*

As with other forms of hyperhidrosis (HH), palmar and plantar HH can create serious physical, professional, and social limitations that affect quality of life (QOL) and thereby cause individuals to seek treatment. In a survey conducted in 2003 of a nationally representative sample of 150,000 households in the United States, the

prevalence of HH was 2.9% (6800 individuals). When that result was extrapolated to the US population, HH was projected to be 2.8%, or 7.8 million individuals.<sup>1</sup> Of these individuals, approximately 25% to 50% are projected to have palmar HH alone or in combination with another form of HH.<sup>2,3</sup> Dermatology Life Quality Index (DLQI) scores showed palmar HH was more debilitating than psoriasis that requires inpatient care, eczema that requires inpatient care, or contact dermatitis.<sup>4</sup> Because of the importance and constant use of one's hands in professional and social situations, adequate treatment of palmar HH is critical. Although plantar HH is considered less outwardly obvious than axillary, palmar, or facial HH, patients with this condition may seek treatment because of the distress and self-consciousness it causes. Plantar HH also may create physical discomfort and inconvenience, which could negatively impact an individual's QOL.

This article presents an overview of suggested practices for botulinum toxin type A (BTX-A; Botox®) use (eg, dilution, duration of stability, contraindications, warnings), specific best practice recommendations regarding its use in the treatment of palmar and plantar HH (eg, syringe selection, injection technique, dose, injection grid), and a review of insurance reimbursement options for HH treatment.

## General BTX-A Recommendations

*Clostridium botulinum* type A (Botox; approved by the US Food and Drug Administration for the treatment of severe primary axillary HH that is inadequately managed with topical agents) is supplied in vials containing 100 U of vacuum-dried neurotoxin complex. According to the BTX-A full prescribing information, each vial can be reconstituted using 1 to 8 mL of 0.9% nonpreserved saline to create a final dose of 1.25 to 10 U per 0.1 mL.<sup>5</sup> In the pivotal clinical trials for treatment

---

Dr. Glaser is from the Department of Dermatology, Saint Louis University, Missouri. Dr. Hebert is from the Departments of Dermatology and Pediatrics, The University of Texas Medical School at Houston. Dr. Pariser is from the Department of Dermatology, Eastern Virginia Medical School, Norfolk. Dr. Solish is from Women's College Hospital, University of Toronto, Ontario, Canada.

Dr. Glaser is on the advisory board for and has received research grants from Allergan, Inc. Dr. Hebert is a consultant and researcher for Allergan, Inc. Dr. Pariser is an advisory board member and consultant for and has received research support from Allergan, Inc. Dr. Solish has received honoraria for speaking and will be conducting a research trial for Allergan, Inc.

Table 1.

**Recommendations for Botulinum Toxin Type A Reconstitution and Handling**

Parameter	Recommendation
Diluent	0.9% nonpreserved saline <sup>5</sup> (preferred); 0.9% preserved saline
Concentration	4 U per 0.1 mL using 2.5 mL of diluent, <sup>9</sup> 2.5 U per 0.1 mL using 4 mL of diluent, <sup>5</sup> or any convenient concentration to deliver required units per injection site
Storage before reconstitution	2°C to 8°C for ≤24 mo <sup>5</sup>
Storage after reconstitution	4 h at 2°C to 8°C <sup>5</sup> ; ≤6 wk at 4°C <sup>7</sup>
Handling	Special precautions not required

of axillary HH, a vial of BTX-A was diluted with 4 mL of 0.9% nonpreserved saline. However, in the practice setting, physicians use a range of dilutions and injection volumes, depending primarily on the number of units to be injected at each site and the physician's preference. It has been suggested that preserved saline can be used to dilute the drug without affecting efficacy and may cause less injection pain than dilutions with nonpreserved saline.<sup>6</sup> Regardless of the diluent used, the reconstituted BTX-A solution should be clear, colorless, and free of particulate matter.<sup>5</sup>

Although the full prescribing information recommends that BTX-A be used within 4 hours after reconstitution,<sup>5</sup> results of a multicenter double-blind study demonstrated that BTX-A reconstituted with nonpreserved saline was efficacious in treating glabellar frown lines after up to 6 weeks of storage at 4°C.<sup>7</sup> Our experiences also support using BTX-A more than 4 hours after reconstitution but only if the reconstituted solution is stored properly. Loss of BTX-A potency at the air-solution interface is a common concern that has led to the recommendation to avoid agitation and foam during reconstitution. Similar to findings by Trindade de Almeida and colleagues,<sup>8</sup> our clinical experiences suggest that BTX-A does not require special care when handling. See Table 1 for a summary of reconstitution and handling recommendations.<sup>5,7,9</sup>

Patients should be educated about the possible adverse effects of BTX-A. The long safety history of the drug, the low probability of any adverse effects occurring, and the fact that most

adverse effects are mild and transient should be emphasized.<sup>5,10</sup>

In addition, it is important to confirm that the patient does not have any contraindications to BTX-A therapy, such as infection at the proposed injection site(s) and known hypersensitivity to any ingredient in the formulation, including albumin.<sup>5</sup> Caution is recommended when using this agent in individuals with peripheral motor neuropathic diseases or neuromuscular functional disorders, as they are at risk of clinically significant systemic side effects (eg, myasthenia gravis, Lambert-Eaton syndrome); as coadministration with aminoglycosides or other agents interfering with neuromuscular-transmission, which may potentiate the effect of BTX-A; in individuals with inflammatory skin conditions at the injection site; and in pregnant (pregnancy category C) or lactating females (it is unknown if the toxin is excreted in human milk or affects an infant's nervous system).<sup>5,11</sup> Refer to the BTX-A full prescribing information for complete information.

**Diagnosis and Detection**

*Palmar HH*—In our experience, fewer patients seek treatment for palmar HH than for axillary HH. In a recent study of 508 patient records, approximately 45% of patients presented with palmar HH.<sup>3</sup> From our observations, the patient population seeking treatment is young and is more often male than female. It has been hypothesized that more males seek treatment for palmar HH because they are more often

## Palmar and Plantar HH

employed in professions that require constant use of their hands (eg, construction, repairs).

Generally, the diagnosis of palmar HH is straightforward. (See the Glaser et al<sup>12</sup> article in this supplement.) There are few secondary causes of palmar HH, unless it presents unilaterally. The Minor starch-iodine test is of limited utility for defining the affected area of sweating because palmar HH generally involves the entire volar surface of the palms and digits. Some patients sweat on the non-volar surface of their fingers.

**Plantar HH**—In our individual clinical experiences, the number of patients who seek treatment for plantar HH is approximately one half of those who seek treatment for palmar HH. We speculate that more patients find plantar HH less problematic than other forms of focal HH because it is less obvious and easier to manage with lifestyle modifications, such as choice of footwear, wearing socks, or using powders. The diagnosis of plantar HH also is straightforward. (See the Glaser et al<sup>12</sup> article in this supplement.) As with palmar HH, sweating may occur on the nonvolar surface of the feet. Maceration rarely is observed with plantar HH but can occur.

### Initial Treatment Algorithm for Palmar and Plantar HH

Treatment of either palmar or plantar HH often begins with topical therapy (eg, aluminum chloride). Topical therapy is the simplest treatment, with the potential to produce an acceptable degree of efficacy. Most insurance companies require documentation that topical therapy has failed before approving other treatment options. Two weeks of treatment usually are sufficient to determine a topical agent's efficacy; however, some insurance companies may require a longer trial. Drawbacks of topical agents include skin irritation, messiness (eg, getting into webs), and staining. For plantar HH, patients should be reminded not to put on their socks until the product dries completely; ideally, there should be no occlusion.

Tap water iontophoresis (TWI) may be considered a second-line treatment. This modality can produce good results with proper use. The procedure initially is administered in the physician's office. If effective, it is then taught to patients who may choose to purchase a unit for self-administration at home rather than continually returning to the dermatologist's office for treatment. TWI can be messy (eg, spilling the large trays of water) and is time consuming. Some patients do not like the sensation it creates (eg, uncomfortable, annoying); other patients are resistant to the commitment

they must make to the procedure and the frequency of maintenance treatments. Because of the pain associated with BTX-A injections in the sole, many patients accept TWI as their mainstay of plantar HH treatment.

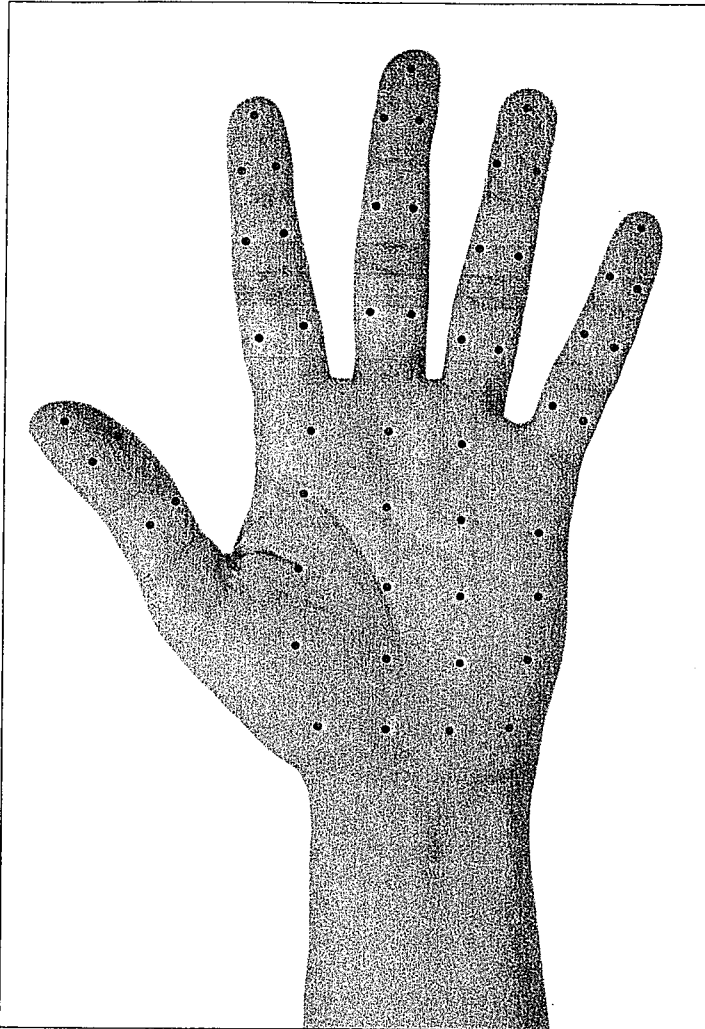
If topical therapy and TWI fail, are unavailable, or are deemed unsatisfactory by the patient, the next logical treatment option is BTX-A. Although BTX-A treatment is more invasive than topical therapy and TWI, we believe that it is safer than oral medications or endoscopic transthoracic sympathectomy; additionally, it is associated with fewer adverse effects than those treatments.<sup>13-15</sup> However, for individuals experiencing several areas of focal HH, oral medications may be preferable to multiple local treatments.

### Best Practice Techniques

Overall, the procedures and techniques used to treat axillary, palmar, and plantar HH are the same. However, more skill and precision are required to treat palmar HH because of the dense innervation and vascularity located superficially in the palms. Improper injections may cause pain during the procedure and muscle weakness after. Likewise, expertise is required to treat plantar HH because of the dense innervation present in the soles. The plantar nerves and vessels in the foot are deeper than the palm because of a thicker stratum corneum; thus, there is less risk of muscle weakness or other complications with injections in the foot. However, the stratum corneum thickness on the sole can vary, so administering BTX-A consistently, correctly, and at the right depth is difficult; response rates can be lower and may depend on the technique used.

**Dilution and Syringe Selection**—As mentioned earlier, the BTX-A (Botox) prescribing information recommends diluting BTX-A in 4 mL of 0.9% nonpreserved saline. Some physicians prefer to use a 2.5-mL dilution, which allows the drug to be drawn up in five 0.5-cc syringes; in turn, this allows 4 U BTX-A per 0.1 mL to be injected or 2 U per 0.05 mL. We recommend a 4-mL dilution rather than a 2.5-mL dilution because it allows more volume for injection and decreases the number of units deposited at each injection site, minimizing potential muscle weakness that may occur through diffusion. When using a 4-mL dilution, we recommend the BTX-A be drawn up in four 1-cc syringes, which will provide 2.5 U per 0.1 mL of injection, or approximately 1.5 U per 0.05 mL of injection.

In general, plastic single-use syringes are recommended. Insulin syringes often are found to be convenient because there is no space at the hub,



**Figure 1.** Injection grid for palmar hyperhidrosis.

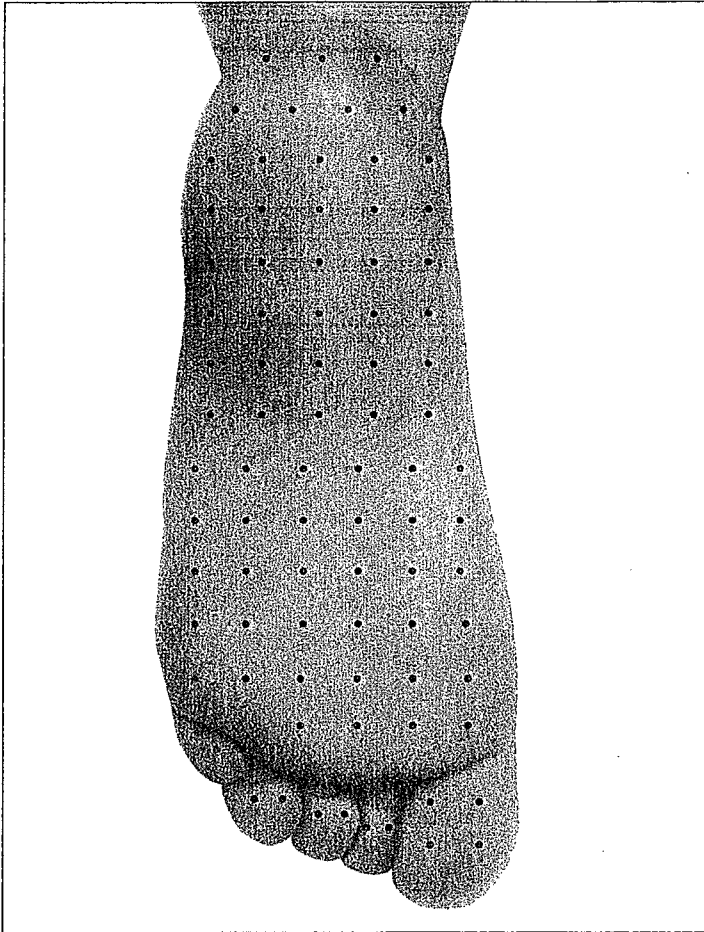
where the drug may be wasted. A 30-gauge needle is standard, but several experts have reported reduced patient pain with a 31- or 32-gauge needle.<sup>16</sup> If the syringe allows for an interchangeable needle, it is recommended to select a syringe that uses a luer lock connection. A permanently attached needle allows for less waste, but it can become dull after several injections. The choice of syringe and needle depends primarily on the physician's preference. One study evaluated the use of the Dermojet<sup>®</sup> to reduce the pain of injection in palmar HH; however, the results indicated that BTX-A administered by conventional injection was more effective than BTX-A administered by Dermojet.<sup>17</sup>

**Injection Technique**—The desired injection depth is the deep dermis, at or near the junction with the subcutaneous tissue, which is where the sweat glands are located.<sup>18</sup> Physicians must

keep in mind that for palmar HH, it is important not to inject the medication too deep because it may lead to muscle weakness—especially over the thenar eminence where the subcutis is thin—which could result in decreased manual dexterity and grip strength. For plantar HH, the stratum corneum in most patients is thinner at the arch and the center of the foot than in other areas. This technique does not prevent muscle weakness because the diffusion pattern of the injected volume is unpredictable and may affect some of the musculature. Complications from injecting a nerve or artery rarely arise. Mechanical needle flanges have been recommended to assist in controlling the depth of injection; however, uniform injection depth is not appropriate in treating palmar HH because of the varied thickness of the stratum corneum and tissue layers in different areas of the palm and digits, and sole.<sup>19</sup>

Injections may cause bleeding and extrusion of BTX-A. To minimize loss of drug, some of us suggest injecting at an oblique angle to create a longer injection track. Another method is to remove one's thumb from the plunger of the syringe and allow a few seconds to pass so that the pressure normalizes between the needle and tissue before withdrawing the needle. With each injection, a small amount of blanching is expected when the drug is correctly injected intradermally.

**Dose and Injection Grid**—The total dose and number of injection sites required to treat palmar and plantar HH vary and are based on the size of the patient's hand or foot. The average total dose is 100 U BTX-A (Botox) per palm (range, 25–220 U) injected in 45 to 50 sites spread approximately 1 to 1.5 cm apart. Doses of 2.5 or 5 U BTX-A per site in the palms have been shown to create ovals of anhidrosis approximately 1.7 to 2 cm in diameter.<sup>20</sup> The higher dose (5 U) did not result in significantly greater coverage than the lower dose. Thus, we agree that injection-site volume should remain between 0.05 and 0.1 mL because larger volumes have greater potential to cause weakness through diffusion into the subcutaneous muscle and may extrude from the injection site. We agree that to achieve optimal treatment outcomes, the goal is to create confluent overlapping anhidrotic spots through



**Figure 2.** Injection grid for plantar hyperhidrosis.

multiple intradermal injections close to the level of the sweat glands. These doses are recommended by us and have been reported in previously published trials<sup>17,20-35</sup>; they are not strict limitations to the dose that may be used. It is more important that the entire affected area is treated with a minimum of 2 to 3 U BTX-A per site, spaced no more than 1.5 cm apart to ensure overlapping BTX-A halos for overall coverage.

The suggested injection grid for palmar HH treatment with BTX-A is shown in Figure 1. Two or 3 sites are injected in the distal phalanx of the hand because it may be a problematic sweating area and is in constant use. Two sites are injected in both the middle and proximal phalanges. About 15 to 20 sites are injected in the palm approximately 1 to 1.5 cm apart. The dominant writing hand also should receive a row of injections beginning at the base of the fifth finger and continuing to the wrist midway between the palm and dorsal surface to provide maximal dryness when writing.

Some patients may require injections in the distal dorsal areas of the fingers or in the webs of the fingers. We suggest beginning the series of injections at the fingertips and moving in a line through the palm and toward the wrist. After all the fingers and the palm have been injected, the patient's dominant hand should be repositioned to inject the medial edge.

The average BTX-A (Botox) dose for plantar HH is 150 to 250 U per sole, depending on the size of the foot, using 2 to 3 U (0.05–0.1 mL) at each injection site. We suggest using an injection grid that follows the same principles shown in the grid for the palm (Figure 2). Two variations for treating plantar HH are spreading the injection sites so they are approximately 2 cm apart and using fewer injections in the toes because they are smaller than fingers. The injection procedure for the sole usually takes longer to perform because of the larger surface area. These doses are recommended by us and have been reported in previously published trials<sup>21,23,30,36,37</sup>; they are not strict limitations to the dose that may be used. It is more important that the entire affected area be treated with a minimum of 2 to 3 U BTX-A per site, spaced approximately 2 cm apart to ensure overlapping BTX-A halos for overall coverage.

*Anesthesia*—As previously mentioned, the palms, digits, and soles are highly innervated; therefore, adequate anesthesia is important for patient comfort during BTX treatment. Few patients are able to undergo a series of injections without anesthesia. Topical anesthetics used for cosmetic procedures, such as a eutectic mixture of local anesthetics or topical lidocaine 4%, usually are not effective in penetrating the thick stratum corneum of the sole. Vibration anesthesia to mask the pain has demonstrated variable success. Some patients achieve adequate anesthesia with the use of one massager on the dorsal surface of the hand or foot and one massager on the volar surface of the palm or sole. Other patients find this method insufficient when used alone or find the vibration annoying. Obtaining the correct massager and teaching your staff how to effectively coordinate its use with the injections can be difficult. If a massager is used, we suggest that it should be covered with a glove to protect it from blood contamination.

Nerve blocks have been the gold standard of anesthesia for palmar and plantar HH. Wrist blocks generally involve the ulnar and median nerves, and sometimes the radial nerve. For plantar HH, the posterior tibial and sural nerves are blocked. Nerve blocks allow for more precise injections and better patient comfort because the hand/foot is completely anesthetized. There is a low incidence of paresthesia, and permanent nerve damage is rare.<sup>18,34,38,39</sup> However, some patients do not like remaining anesthetized for extended time after the procedure. If both hands or feet are treated at the same time using nerve blocks, the patient will require assistance leaving the office and at home for several hours after the procedure.

More recently, cryoanesthesia using ice combined with pressure has become more prevalent. In our experience, this method provides satisfactory anesthesia with complete safety. Cold packs, liquid nitrogen, or ethyl chloride also may be used instead of ice. In many cases, our patients with palmar HH who previously received nerve blocks and later tried cryoanesthesia have preferred the latter method and rarely have asked for nerve blocks in subsequent treatments. Although this technique has been successful for palmar HH, it may be less effective in pain relief if used as the only anesthesia for plantar HH injections because of the thicker stratum corneum on the sole and some of the thicker regions of the foot. A combination of anesthesia techniques may alleviate more pain than a single technique. For plantar HH, vibration and cryoanesthesia can be used in combination.

When using cryoanesthesia, it is suggested to freeze gauze pads into the ice to help the assistant maintain a better grip on the ice as it melts. Another option is to freeze small balloons filled with water so that the patient's hand does not become wet as the ice melts during the procedure. The assistant should be aware that as the ice melts in the balloon, the temperature may increase slightly; thus, a new piece of ice should be used if the anesthesia is becoming inadequate. One benefit of using ice rather than other numbing products is that the ice molds to the shape of the fingers and provides a greater anesthetized surface area. The assistant should wear insulated thermal gloves under the standard vinyl or latex gloves when handling the ice for the procedure.

When performing cryoanesthesia on the palm, placing an absorbent towel or drape under the hand receiving the treatment helps to soak up the melted ice. We suggest starting injections at

the fingertip, which is the most sensitive area, so that throughout the procedure the patient is not preoccupied with anticipating the pain that might be felt in that area. The assistant should place ice on the distal fingertip while applying firm pressure. The ice and pressure should be maintained at the injection site for at least 7 to 10 seconds. Counting the time aloud allows the patient to expect the injection and alleviates what otherwise may be an uncomfortable silence. The injection should be performed quickly after removing the ice because the anesthesia lasts only a few seconds. Immediately after an injection, the assistant should repeat this process at the next injection site. A similar technique would apply for treating the sole for plantar HH.

### Special Considerations

**Palmar HH**—Muscle weakness is the main adverse effect observed in published reports and in our clinical experience.<sup>17,20,22-33</sup> Reports have suggested that muscle weakness may occur in 6% to 77% of patients.<sup>17,20,22-33</sup> (See the Glaser et al<sup>12</sup> article in this supplement.) This wide range indicates the occurrence of this effect may depend on the injection grid, technique, and dilution used. Muscle weakness generally is mild and noticeable only when maximal finger opposition is required, such as when opening a vacuum-sealed jar. Patients usually do not experience difficulty eating, typing, or writing. The duration of effect is transient and usually resolves within a few weeks after the injections.

Another potential temporary adverse effect following treatment is soreness at the injection sites for 1 or 2 days.<sup>20</sup> Six of 19 subjects reported dry skin on the palms that required use of a moisturizer.<sup>27</sup> Otherwise, the use of BTX-A (Botox) has a good safety and tolerability profile.

When treating a patient with palmar HH for the first time, it is recommended to treat the nondominant hand first and then have the patient return in a few weeks with feedback so that any necessary dose adjustments can be made before treating the dominant hand. Results of a Minor starch-iodine test performed at follow-up may be beneficial to detect any pockets of sweating that were not treated adequately.

Patients usually complain of recurrence of sweating first in the digits of the dominant hand. Some experts have speculated that the digits probably are not experiencing a loss of efficacy more quickly than other treated areas but that the recurrence of symptoms is more noticeable in that area because it is used more frequently than other areas of the

## Palmar and Plantar HH

hand. Patients may return for touch-ups between full treatments. If the patient is willing and distance is not a limiting factor, it is best to maintain a staggered alternating treatment regimen for the 2 hands because touch-ups then can be performed on the previously treated hand during a treatment session for the other hand.

Generally, patients receive 2 treatments per year for palmar HH because the duration of effect usually ranges from 5 to 7 months before an unacceptable level of sweating returns. The severity of the patient's palmar HH before treatment does not appear indicative of the duration of efficacy following treatment.<sup>35</sup>

**Plantar HH**—In the published literature, one patient reported weakness of plantar flexor muscles in both feet that resolved in 10 days.<sup>30</sup> Adverse effects included pain on injection and bruising, which are not atypical for BTX treatment.<sup>21,30,36</sup> Otherwise, BTX-A (Botox) therapy demonstrated a good safety and tolerability profile consistent with its use in other therapeutic indications.<sup>21,23,30,36,37</sup>

As with palmar HH, results of a Minor starch-iodine test performed during a follow-up visit may be useful in plantar HH to detect any pockets of sweating not treated adequately during the initial procedure. Generally, patients receive 2 treatments per year for plantar HH because anhidrosis tends to last between 4 and 6 months before an unacceptable level of sweating returns.

Patients may be self-conscious about the odor caused by plantar HH. They may request recommendations on methods to control odor and wetness if they are unable to tolerate or afford BTX-A treatment. Some suggestions that may help are citric acid products or topical antibiotics, in addition to consistently changing socks to maintain dryness.

### Impact on QOL

The discomfort associated with palmar HH can affect professional and personal relationships and functioning. Patients may avoid handshakes as well as sports and other physical activities. Many patients develop habits such as constantly wiping their hands on handkerchiefs or towels. Patients with palmar HH noted the following limitations caused by the disease:

- “She recalled wrapping paper towels around her pencils in school so she could hold them and placing paper towels between her hand and the paper to avoid smudging when writing.”<sup>40</sup>
- “. . . [H]er chief occupational complaint was that intravenous tubing slipped out of her hands because of her HH, limiting

her ability to perform her duties [a nurse] at work. Moreover, she constantly had to change her gloves because they rapidly filled with sweat. When driving an automobile, she would direct air vents toward her hands so they would not slip off the steering wheel.”<sup>40</sup>

- “. . . [H]e is convinced that a suspect literally slipped out of his hands during an attempted arrest because his hands were so sweaty. Additionally, his sweaty palms limited his ability to perform well on the police academy pistol range test because his fingers slipped on the pistol.”<sup>40</sup>
- “She constantly carried a rag or paper towels with her and reported that she once shorted out a computer keyboard because of her sweat. She could not handwrite without the ink smudging.”<sup>40</sup>
- “At a party, she would always hold a very cold drink in her right hand so that when shaking hands, the other person would feel the wet hand and assume that the wetness was from the drink.”
- “At a very important social event, he had the opportunity to shake hands with Vice President Cheney. After the handshake, the vice president looked at his own hand, made a facial grimace, and wiped his hand on his trousers.”

Many patients with plantar HH complain they are unable to wear flip-flops or other open footwear without slipping and sliding in them, which tends to hinder movement during the summer months and at events such as weddings. One case report described the patient as stating, “She . . . noted that if she wore shoes without socks, her feet would slip and slide inside the shoes.” Another patient described her feet as if “they were in a sauna” when certain types of shoes were worn.

Several studies measuring the effects of BTX-A (Botox) treatment have shown substantial improvements in patient QOL. The symptoms of palmar HH have a more profound effect in increasing overall patient dissatisfaction with their lifestyle (based on the DLQI) than do the symptoms of severe psoriasis, eczema, or atopic dermatitis.<sup>4</sup> Thus, palmar HH treatment offers potential for improving QOL. Tan and Solish<sup>22</sup> reported a significant improvement in DLQI scores with treatment ( $P < .02$ ), as did an analysis by Campanati and colleagues<sup>23</sup> ( $P < .001$ ). Swartling and colleagues<sup>41</sup> reported an 80% improvement in the DLQI score in treated patients who did not experience relapse ( $P = .00019$ ). DLQI scores significantly

decreased in the following categories: embarrassment/self-consciousness; interference in shopping/housework/gardening; influencing clothing choices; social/leisure activities, sports; working/studying; relationships with partners, close friends, or relatives; sexual difficulties; and treatment being time consuming or messy ( $P < .05$  for all). A study by Vadoud-Seyedi<sup>36</sup> evaluated 10 subjects with plantar HH for up to 8 months following BTX-A treatment. Results showed that self-assessment reports from 7 of 10 subjects found that the subjects were satisfied with treatment and experienced improved social performance.<sup>36</sup>

### Insurance Reimbursement

The insurance reimbursement environment for HH is becoming less restrictive with the increasing amount of QOL data being published to support the personal, psychologic, social, and professional impact HH has on patients. Many insurance companies no longer view treatment as a cosmetic matter and understand it is a medical necessity. However, there still can be challenges navigating through the insurance reimbursement process.

Although not a guarantee for coverage, precertification does help increase the likelihood of insurance reimbursement and should become standard office practice for patients with HH.<sup>42</sup> A standardized letter justifying the need for BTX-A treatment also may be useful. Most insurance companies request that the letter include the patient's Hyperhidrosis Disease Severity Scale score or other measures of the impact of HH on the patient, in addition to a list of personal and professional limitations that have resulted from the condition. Documentation of past treatments and the reason for failure or discontinuation of the therapy can be helpful. Supplying QOL data from the published literature also will help strengthen support for reimbursing treatment and potentially increase awareness among decision makers in the insurance industry.<sup>42</sup>

Revisions have been made to the International Classification of Diseases, Ninth Revision, Clinical Modification (ICD-9-CM), and the CPT® (*Current Procedural Terminology*) codes, to help improve access to care for individuals with HH.<sup>42-45</sup> Since October 2004, HH has been recognized as a primary diagnosis with ICD-9-CM codes 705.21 and 705.22 for primary and secondary focal HH, respectively.<sup>43</sup> Another recent development is the designation of CPT codes for chemodestruction of eccrine glands (eg, BTX-A therapy).<sup>44,45</sup> Since 2006, the CPT code for axillary HH is 64650; for HH in other areas, such as the scalp, face, and neck, the code is

64653 (Table 2). For both codes, it is necessary to report the specific service and code for the specific substance(s) or drug(s) provided. The CPT code for palmar and plantar HH is 64999, which applies to chemodestruction of the extremities [eg, hands, feet].<sup>45</sup> Usually, this code will not be processed electronically and generates a query from the insurance company for a manual claim to be submitted with supporting medical information and a statement of medical necessity. No specific level of insurance reimbursement is assigned to this code, so the reviewer decides the amount of payment each time the code is used. If the procedure is reimbursed, the physician and patient should note that some insurance companies may limit the total BTX-A dose or frequency of treatment.<sup>42</sup>

Evaluation and management services can be submitted for an insurance claim at the first visit but not for subsequent visits that monitor the patient's response to treatment (Table 2). The CPT 25 modifier (a 2-digit code listed after the procedure code) should be used if a separate service is performed at the same time as the treatment. Generally, gravimetric measurements and Minor starch-iodine tests are not reimbursed. Nerve blocks, if used, vary in coverage.

When submitting a claim for BTX-A (Botox), it is important to use the National Drug Code for the therapeutic product, not the cosmetic product, to decrease the risk of having a claim rejected. BTX-A can be billed using the Healthcare Common Procedure Coding System code J0585 (per unit).<sup>46</sup> Some insurance claim submission programs do not accommodate 3 digits for units of BTX-A. A solution is to submit 2 claims that add up to the total amount of BTX-A used (eg, 99 U for the first claim, the remainder for the second claim). If the physician does not want the practice to bear the risk for drug reimbursement or handle the associated paperwork, he/she can write a prescription for BTX-A, with a note that it is not for cosmetic use, and have the patient bring it in at the time of treatment. For queries regarding BTX-A (Botox), there is an insurance reimbursement hotline that can provide support and resources.

Although insurance reimbursement is more consistent now, sometimes BTX-A treatment will not be covered. In such cases, it is important to discuss alternative treatments with the patient. Some patients may opt to have only their dominant hand treated as a compromise between personal satisfaction and out-of-pocket constraints. For patients who may not have medical care coverage but have prescription coverage, it may be helpful for the physician to write a prescription for BTX-A that the patient can bring



Table 2.

**Current ICD-9-CM and CPT® Codes for Select Focal Hyperhidrosis Diagnoses and Therapies\*42-45**

Diagnosis/Treatment	Current Code(s)	Notes
Primary focal HH	ICD-9-CM, 705.21	Former ICD-9-CM, 780.80
Secondary focal HH	ICD-9-CM, 705.22	Former ICD-9-CM, 780.80
Evaluation and management services, when applicable	CPT; 99211, 99212, 99213, or others (if appropriate)	The CPT 25 modifier may be used if applicable†
BTX-A	CPT, 64650 (chemodenerivation of eccrine glands; both axillae)	Providers must "report the specific service in conjunction with code(s) for the specific substance(s) or drug(s) provided" <sup>45</sup>
	CPT, 64653 (chemodenerivation of eccrine glands; other area(s) [eg, scalp, face, neck] per day)	Providers must "report the specific service in conjunction with code(s) for the specific substance(s) or drug(s) provided" <sup>45</sup>
	CPT, 64999 (chemodenerivation of extremities [eg, hands, feet])	Often, this code cannot be processed electronically and usually generates a query from the insurance company for a manual claim with supporting medical information and a statement of medical necessity. No specific level of insurance reimbursement is assigned to this code

\*ICD-9-CM indicates International Classification of Diseases, Ninth Revision, Clinical Modification; CPT, *Current Procedural Terminology*; HH, hyperhidrosis; BTX-A, botulinum toxin type A.

†A CPT modifier is a 2-digit code listed after the procedure code.

Adapted with permission from *Cutis*. 2006;77(suppl 5):42-46. ©2006, Quadrant HealthCom Inc.

in at the time of treatment. As a result, the patient only pays for the procedure out-of-pocket, assuming BTX-A is covered by his/her prescription plan.

**Comment**

Palmar and plantar HH can cause much distress, discomfort, self-consciousness, and inconvenience for patients with either of these conditions, which may limit a patient's personal, professional, and social functioning and reduce his/her QOL. Because of the importance and constant use of one's hands and feet, adequate treatment of palmar and plantar HH is essential. Topical agents and TWI can provide control, but in more severe cases, they are generally inadequate. In such cases, it is important that physicians are aware that BTX-A is a treatment

option for these forms of HH. To achieve successful clinical outcomes and to maintain safety when injecting the palm and/or sole, which are highly innervated and have dense vasculature, it is critical that physicians understand the proper techniques for BTX-A injections.

**REFERENCES**

1. Strutton DR, Kowalski JW, Glaser DA, et al. US prevalence of hyperhidrosis and impact on individuals with axillary hyperhidrosis: results from a national survey. *J Am Acad Dermatol*. 2004;51:241-248.
2. International Hyperhidrosis Society. About hyperhidrosis: epidemiology of primary hyperhidrosis. Available at: [http://www.sweathelp.org/English/HCP\\_Hyperhidrosis\\_Epidemiology.asp](http://www.sweathelp.org/English/HCP_Hyperhidrosis_Epidemiology.asp). Accessed December 14, 2006.

3. Lear W, Kessler E, Solish N, et al. An epidemiological study of hyperhidrosis. *Dermatol Surg.* 2007;33(1 spec no): S69-S75.
4. International Hyperhidrosis Society. Procedure and practice overview series: ice analgesic technique for palmar Botox® injections [video]. Available at: [http://sweathelp.org/English/HCP\\_Resources\\_Procedure\\_Practice.asp](http://sweathelp.org/English/HCP_Resources_Procedure_Practice.asp). Accessed December 14, 2006.
5. Botox [package insert]. Irvine, Calif: Allergan, Inc; 2006.
6. Alam M, Dover JS, Arndt KA. Pain associated with injection of botulinum A exotoxin reconstituted using isotonic sodium chloride with and without preservative: a double-blind, randomized controlled trial. *Arch Dermatol.* 2002;138:510-514.
7. Hexsel DM, de Almeida AT, Rutowitsch M, et al. Multicenter, double-blind study of the efficacy of injections with botulinum toxin type A reconstituted up to six consecutive weeks before application. *Dermatol Surg.* 2003;29:523-529.
8. Trindade de Almeida AR, Kadunc BV, Di Chiacchio N, et al. Foam during reconstitution does not affect the potency of botulinum toxin type A. *Dermatol Surg.* 2003;29:530-531.
9. Botox Cosmetic [package insert]. Irvine, Calif: Allergan, Inc; 2005.
10. Alam M, Dover JS, Klein AW, et al. Botulinum A exotoxin for hyperfunctional facial lines: where not to inject. *Arch Dermatol.* 2002;138:1180-1185.
11. Matarasso SL. Complications of botulinum A exotoxin for hyperfunctional lines. *Dermatol Surg.* 1998;24:1249-1254.
12. Glaser DA, Hebert AA, Pariser DM, et al. Focal hyperhidrosis: scope of the problem. *Cutis.* 2007;79(suppl 5): 5-17.
13. Atkins JL, Butler PE. Hyperhidrosis: a review of current management. *Plast Reconstr Surg.* 2002;110: 222-228.
14. Hornberger J, Grimes K, Naumann M, et al, the Multi-Specialty Working Group on the Recognition, Diagnosis, and Treatment of Primary Focal Hyperhidrosis. Recognition, diagnosis, and treatment of primary focal hyperhidrosis. *J Am Acad Dermatol.* 2004;51: 274-286.
15. Lin T-S, Wang N-P, Huang L-C. Pitfalls and complication avoidance associated with transthoracic endoscopic sympathectomy for primary hyperhidrosis (analysis of 2200 cases). *Int J Surg Investig.* 2001;2:377-385.
16. Carruthers J, Fagien S, Matarasso SL, and the Botox Consensus Group. Consensus recommendations on the use of botulinum toxin type A in facial aesthetics. *Plast Reconstr Surg.* 2004;114(suppl 6):3S-22S.
17. Naumann M, Bergmann I, Hofmann U, et al. Botulinum toxin for focal hyperhidrosis: technical considerations and improvements in application [letter]. *Br J Dermatol.* 1998;139:1123-1124.
18. Fujita M, Mann T, Mann O, et al. Surgical pearl: use of nerve blocks for botulinum toxin treatment of palmar-plantar hyperhidrosis. *J Am Acad Dermatol.* 2001;45: 587-589.
19. Trindade de Almeida AR, Boraso RZ. Palmar hyperhidrosis. In: Trindade de Almeida AR, Hexsel DM, eds. *Hyperhidrosis and Botulinum Toxin*. São Paulo, Brazil: Metropole Industria Grafica Ltd; 2004:155-162.
20. Saadia D, Voustantiok A, Wang AK, et al. Botulinum toxin type A in primary palmar hyperhidrosis: randomized, single-blind, two-dose study. *Neurology.* 2001;57: 2095-2099.
21. Naumann M, Hofmann U, Bergmann I, et al. Focal hyperhidrosis: effective treatment with intracutaneous botulinum toxin. *Arch Dermatol.* 1998;134:301-304.
22. Tan SR, Solish N. Long-term efficacy and quality of life in the treatment of focal hyperhidrosis with botulinum toxin A. *Dermatol Surg.* 2002;28:495-499.
23. Campanati A, Penna L, Guzzo T, et al. Quality-of-life assessment in patients with hyperhidrosis before and after treatment with botulinum toxin: results of an open-label study. *Clin Ther.* 2003;25:298-308.
24. Holmes S, Mann C. Botulinum toxin in the treatment of palmar hyperhidrosis [letter]. *J Am Acad Dermatol.* 1998;39:1040-1041.
25. Lowe NJ, Yamauchi PS, Lask GP, et al. Efficacy and safety of botulinum toxin type A in the treatment of palmar hyperhidrosis: a double-blind, randomized, placebo-controlled study. *Dermatol Surg.* 2002;28:822-827.
26. Naumann M, Flachenecker P, Bröcker E-B, et al. Botulinum toxin for palmar hyperhidrosis. *Lancet.* 1997; 349:252.
27. Naver H, Swartling C, Aquilonius S-M. Palmar and axillary hyperhidrosis treated with botulinum toxin: one-year clinical follow-up. *Eur J Neurol.* 2000;7:55-62.
28. Naver H, Swartling C, Aquilonius S-M. Treatment of focal hyperhidrosis with botulinum toxin type A. brief overview of methodology and 2 years' experience. *Eur J Neurol.* 1999;6(suppl 4):S117-S120.
29. Rusciani L, Severino E, Rusciani A. Type A botulinum toxin: a new treatment for axillary and palmar hyperhidrosis. *J Drugs Dermatol.* 2002;2:147-151.
30. Sevim S, Dogu O, Kaleagasi H. Botulinum toxin-A therapy for palmar and plantar hyperhidrosis. *Acta Neurol Belg.* 2002;102:167-170.
31. Shelley WB, Talanin NY, Shelley ED. Botulinum toxin therapy for palmar hyperhidrosis. *J Am Acad Dermatol.* 1998;38:227-229.
32. Simonetta Moreau M, Cauhepe C, Magues JP, et al. A double-blind, randomized, comparative study of Dysport vs Botox in primary palmar hyperhidrosis. *Br J Dermatol.* 2003;149:1041-1045.
33. Solomon BA, Hayman R. Botulinum toxin type A therapy for palmar and digital hyperhidrosis. *J Am Acad Dermatol.* 2000;42:1026-1029.

## Palmar and Plantar HH

34. Trindade de Almeida AR, Kadunc BV, Martins de Oliveira EM. Improving botulinum toxin therapy for palmar hyperhidrosis: wrist block and technical considerations. *Dermatol Surg.* 2001;27:34-36.
35. Vadoud-Seyedi J, Heenen M, Simonart T. Treatment of idiopathic palmar hyperhidrosis with botulinum toxin. report of 23 cases and review of the literature. *Dermatology.* 2001;203:318-321.
36. Vadoud-Seyedi J. Treatment of plantar hyperhidrosis with botulinum toxin type A. *Int J Dermatol.* 2004;43:969-971.
37. Vadoud-Seyedi J, Simonart T, Heenen M. Treatment of plantar hyperhidrosis with dermojet injections of botulinum toxin [letter]. *Dermatology.* 2000;201:179.
38. Blaheta HJ, Vollert B, Zuder D, et al. Intravenous regional anesthesia (Bier's block) for botulinum toxin therapy of palmar hyperhidrosis is safe and effective. *Dermatol Surg.* 2002;28:666-671.
39. Campanati A, Lagalla G, Penna L, et al. Local neural block at the wrist for treatment of palmar hyperhidrosis with botulinum toxin: technical improvements. *J Am Acad Dermatol.* 2004;51:345-348.
40. Pariser DM. Clinical considerations for the treatment of hyperhidrosis: case reports. *Cutis.* 2006;77(suppl 5):47-51.
41. Swartling C, Naver H, Lindberg M. Botulinum A toxin improves life quality in severe primary focal hyperhidrosis. *Eur J Neurol.* \*2001;8: 247-252.
42. Pariser DM. Importance of patient access to care and insurance reimbursement. *Cutis.* 2006;77(suppl 5): 42-46.
43. Hart AC, Hopkins CA, Ford B, eds. *International Classification of Diseases, 9th Revision: Clinical Modification.* 6th ed. Salt Lake City, Utah: Ingenix, Inc; 2005.
44. American Medical Association. *CPT 2005: Current Procedural Terminology.* Chicago, Ill: American Medical Association; 2004.
45. American Medical Association. *CPT 2006: Current Procedural Terminology.* Chicago, Ill: American Medical Association; 2005.
46. *HCPCS 2005: Healthcare Common Procedure Coding System, Medicare's National Level II Codes.* Salt Lake City, Utah: Ingenix Publishing Group; 2004.