

# Periorbital hyperchromia

## Hiperpigmentação periorbital

### ABSTRACT

Periorbital hyperchromia (dark eye circles) is a recurrent complaint in dermatologic consultations, as it interferes with patients' self esteem. The eyes are central in the communication process, and dark eye circles are very noticeable and make the face look tired; thus they have a considerable impact on patients' quality of life. Although many treatment options are available, publications on periorbital hyperpigmentation are scarce, and the vast majority lack a sound scientific basis to prove their efficacy and duration. This article analyzes the palpebral region's anatomy and periorbital hyperchromia's epidemiology, etiopathogeny, and treatments recommended in the literature.

**Keywords:** hyperpigmentation; eyelids; skin pigmentation; products for eye areas.

### RESUMO

A hiperchromia cutânea periorbital ou "olheira" é queixa comum nos consultórios de dermatologia por interferir na autoestima dos pacientes. Os olhos são o centro das atenções na comunicação, e a "olheira" dificilmente passa despercebida, proporcionando à face aspecto de cansaço, causando importante impacto na qualidade de vida. Há poucas publicações na literatura sobre hiperpigmentação periorbital e, embora as opções de tratamento sejam muito vastas, a maioria carece de embasamento científico que comprove sua eficácia e duração. Este artigo aborda a anatomia da região palpebral, a epidemiologia, a etiopatogenia e os tratamentos propostos na literatura para a hiperchromia periorbital.

**Palavras-chave:** hiperpigmentação; pálpebras; pigmentação da pele; produtos para áreas dos olhos.

### INTRODUCTION

Although periorbital hyperpigmentation (also called peri-palpebral hyperpigmentation, dark eyelids, dark eye circles, dark circles, or simply under-eye circles) is a mere color difference between the palpebral skin and the remaining facial skin, it makes people look tired or older, which negatively affects their quality of life.<sup>1-4</sup>

It has a higher prevalence in individuals with darker skin, hair and eyes, and affects age groups and genders equally. Nevertheless, there are a higher number of complaints from women, especially senior women. There are few studies about the etiology of this condition, however dark eye circles with a vascular component are known to present a dominant autosomal family inheritance pattern.<sup>2,3</sup>

Periorbital hyperpigmentation seems to have multifactorial causes that involve intrinsic factors (determined by the individual's genetics), and extrinsic factors (sun exposure, smoking,

## Review Article

### Authors:

Daniela Moraes Souza<sup>1</sup>  
Cristiane Ludtke<sup>1</sup>  
Emanuelle Rios de Moraes Souza<sup>2</sup>  
Karina Melchiades Pinheiro Scandura<sup>2</sup>  
Magda Blessmann Weber<sup>3</sup>

<sup>1</sup> Dermatology specialist candidate, Universidade Federal de Ciências da Saúde de Porto Alegre (UFCSA) – Porto Alegre (RS), Brazil.

<sup>2</sup> Intern, Dermatology Department, Universidade Federal de Ciências da Saúde de Porto Alegre

<sup>3</sup> Assistant Professor, Universidade Federal de Ciências da Saúde de Porto Alegre

### Correspondence:

Universidade Federal de Ciências da Saúde de Porto Alegre  
Centro de Saúde Santa Marta  
Serviço de Dermatologia  
Rua Capitão Montanha, 27 / 3º andar, sala 324  
90010-040 – Porto Alegre – RS, Brazil  
E-mail: mbw@terra.com.br

Received on: 17/07/2011  
Approved on: 08/09/2011

This study was carried out at the Universidade Federal de Ciências da Saúde de Porto Alegre (UFCSA) – Porto Alegre (RS), Brazil

Conflicts of interests: none  
Financial support: none

alcoholism and sleep deprivation, for instance). However, the presence of melanic pigment and hemosiderotic pigment in the affected sites is a distinctive feature in its etiopathogeny.<sup>2-4</sup>

Melanic hyperpigmentation is more frequent in brunet adults, as a consequence of excessive and cumulative exposure to the sun, which increases the production of melanin, reduces the skin's thickness and increases the dilatation of blood vessels.<sup>2,4,5</sup>

Intense vascularization is mainly found in people belonging to certain ethnic groups such as Arabs, Turks, Hindus, inhabitants of the Iberian Peninsula and their respective descendants. In these ethnicities, its manifestation tends to take place earlier, often during childhood. In those individuals there is no change in the color of the skin; the eyelid appears darkened because the dilated vessels are visible due to the transparency of the skin.<sup>2</sup> In those cases, therefore, the problem is often aggravated when the lower eyelid's vessels are more dilated (e.g., from fatigue, insomnia, oral breathing, crying), causing dermal blood extravasation. The liberation of ferric ions takes place locally, entailing the formation of free radicals that stimulate the melanocytes, which generates melanic pigmentation.<sup>2,4-6</sup>

Other causes noted as being responsible for the appearance of dark eye circles are post-inflammatory hyperpigmentation secondary to atopic and contact dermatitis, sleep deprivation, oral breathing, alcoholism, smoking, use of certain medications (contraceptives, chemotherapy, antipsychotic and some types of eye drops), the presence of palpebral sagging (due to aging) and of disorders that develop with hydric retention and palpebral edema (thyroid disorders, nephropathies, cardiopathies and pneumopathies) – all of which worsen the unattractive appearance of dark eye circles.<sup>2-4,7</sup>

Various treatments have been proposed for periorbital hyperchromia, however there are few studies on their long-term efficacy. The main types of treatment are: topical application of depigmenting products, chemical peelings, dermabrasion, cryosurgery, fillings with hyaluronic acid, intense pulsed light, CO<sub>2</sub>, argon, ruby and excimer lasers.<sup>2-4,6,8-12</sup>

## PALPEBRAL ANATOMY

The eyelids are tegumentary pleats that participate in facial expression and aesthetics, however their main function is to protect the eyeballs through sensorial filtration actions carried out by the palpebral cilia, and the Meibomian and lachrymal glands' secretions. In this manner, the cornea remains hydrated and the closing movements of the eyes function as a barrier to external traumas and prevent the cornea from drying out.<sup>13-17</sup>

The upper eyelid reaches upwards to the eyebrow, which separates it from the forehead. The lower eyelid extends downwards up to the lower border of the orbit, and is delimited by the genian region.<sup>15</sup>

The palpebral fissure, which measures 9–10 mm in adults, is determined by the interaction of the muscles that open and close the eyelids. To open the eyelid, the palpebral elevator muscle is assisted by two other accessory muscles (Muller's and frontalis muscles).<sup>18</sup> The aging process decreases the palpebral fissure's vertical opening, due to the progressive lowering of the

upper eyelid,<sup>14</sup> which is caused by a decrease in the upper eyelid lifter muscle's aponeurosis action.<sup>15</sup> The skin becomes more flaccid, less elastic and has a greater propensity to wrinkle.<sup>16</sup> The orbicular and tarsal muscles, the orbital septum and the conjunctival mucous membrane also go through transformations in the elderly. In addition, gravity and facial expressions influence the mechanical deformation of those structures.<sup>17</sup>

A cohort study with 320 patients (aged 10–89) evaluated participants' eyelids frontally and laterally and found that there is a correlation between a decrease in the palpebral fissure and an increase in the age of patients.<sup>19</sup>

## PALPEBRAL REGION'S SKIN AND SUBCUTANEOUS TISSUE

Palpebral skin is the thinnest in the human body (< 1 mm). Its epidermis is constituted of stratified epithelium, which is very thin (0.4 mm) compared to that of the palmoplantar region (the thickness of which is approximately 1.6 mm).<sup>13</sup>

The nasal portion of the palpebral skin has thinner hair and more sebaceous glands (i.e., it is softer and oilier) than its temporal portion. The transition between the eyelids' thin skin and the remaining facial skin is clinically observable.<sup>13</sup>

The palpebral dermis is composed of loose conjunctive tissue, and is extremely thin in that region. It is absent in the pre-tarsal skin, in the medial and lateral ligaments of the eyelid, where the skin adheres to the underlying fibrous tissue. The thinness of the skin, combined with the lack of fatty tissue, gives that region its characteristic translucency. As a result, the accumulation of melanin and/or vessel dilatation in that region can be easily seen, through transparency, as bilateral homogeneous hyperpigmentation.<sup>2,4,5,13</sup>

## PALPEBRAL REGION'S VENOUS AND LYMPH VASCULARIZATION

The eyelids' arterial irrigation comes through many vessels: the supratrochlear, supraorbital, lachrymal and dorsum of the nose arteries (all originating in the facial artery); the angular artery (originating in the facial artery); the transverse artery (originating in the facial artery); the transverse facial artery (originating in the superficial temporal artery) and the branches of the superficial temporal artery itself.<sup>20</sup> (Figure 1).

Venous drainage (following an external pattern) takes place through the veins associated with these arteries and (following an internal pattern) penetrates the orbit through connections with ophthalmic veins.<sup>20</sup> (Figure 2).

Lymphatic drainage takes place mainly through the parotid lymph nodes; some of the drainage from the medial angle of the eye to the lymph vessels is associated with the angular and facial arteries, towards the submandibular lymph nodes.<sup>20</sup>

## COLOR OF THE SKIN IN THE PALPEBRAL REGION

The palpebral skin's color results from the combination of several factors, some of genetic-racial origin (such as the amount of melanin pigment), others of individual or regional and even gender l origins, such as the thickness of the several components and the blood volume in their vessels.<sup>2,4,5,21</sup>

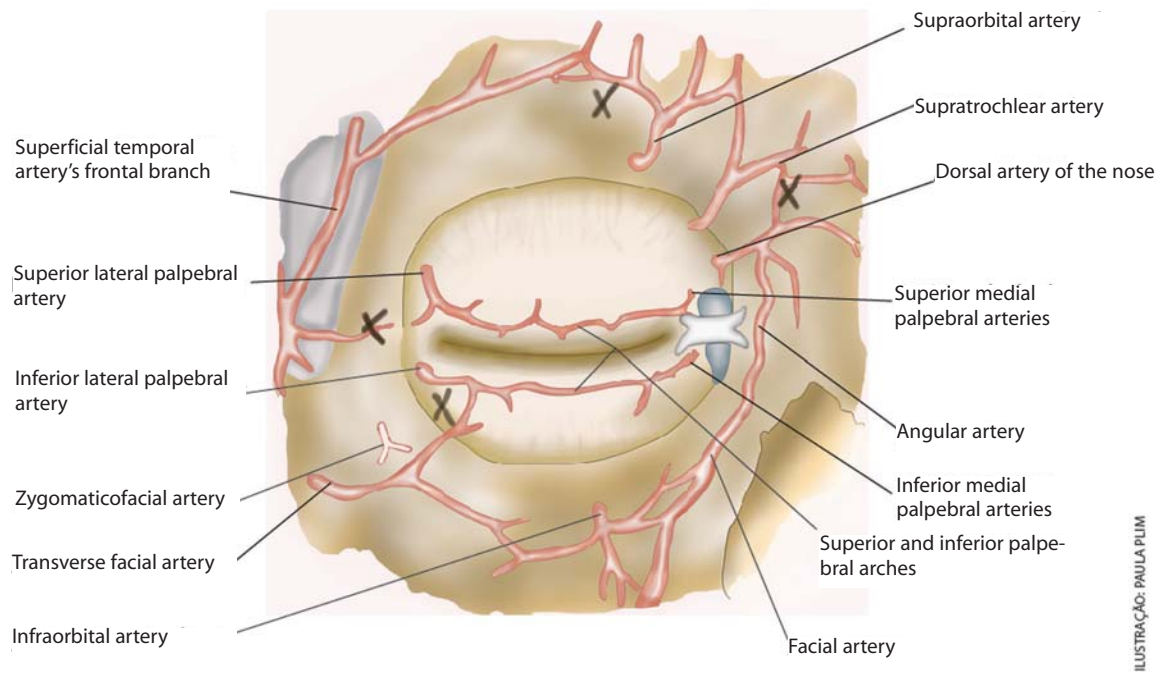


Figure 1 - Eyelids' arterial irrigation

### DARK EYE CIRCLES' ETIOPATHOGENY

There are two types of dark eye circles: those of predominantly vascular etiology and those of predominantly melanic etiology. The majority, however, have mixed origins and are caused by the combination of the pigments melanin and hemosiderin.<sup>2-4</sup>

Dark circles with a predominantly vascular etiology present a pattern of dominant autosomal family inheritance.<sup>2-4</sup> They usually appear earlier, during childhood or adolescence, and are more common in Arab, Turkish, Hindu and Iberian ethnic groups.<sup>2</sup> Diagnosing the type of dark eye circles is carried out by tractioning the lower eyelid in order to better visualize the transparency of the vessels under the skin 2 (Figure 3).

Dark eye circles of predominantly melanic etiology occur more frequently in patients with higher phototypes (Figure 4), but can affect patients with lower phototypes – usually older patients who have had excessive and cumulative sun exposure.<sup>2,22-24</sup>

The physiological cutaneous aging process that leads to palpebral flaccidity and sagging worsens the dark circles' appearance. In addition, excessive exposure to the sun, which causes an increase in pigmentation, a decrease in the thickness of the skin and local vasodilatation, can be a significant etiologic factor for dark eye circles.<sup>2,7,14-16,25</sup>

Due to the vasoconstricting effects of nicotine, smoking causes a pale appearance of the skin in general, increasing the contrast with under-eye circles; alcoholism and sleep deprivation cause vasodilatation and an increase in palpebral blood flow; oral breathing causes edema in the nasal and paranasal mucous membrane, obstructing the palpebral veins' drainage and leading to blood stasis and dark circles.<sup>2,25</sup>

The use of hormonal replacement therapy and contraceptives, and menstruation and pregnancy worsen under-eye circles due to the hormonal stimulus of melanin production.<sup>2,3,22,25</sup>

The use of vasodilating drugs and eye drops based on si-

milar analogous prostaglandins for the treatment of glaucoma causes, in addition to palpebral hyperpigmentation, the reabsorption of orbital fat.<sup>3,26</sup>

A deficiency in vitamin K, vital in the blood coagulation process, can cause small hemorrhages and cause dark circles.<sup>2,3,25</sup>

### EPIDEMIOLOGY

No epidemiological studies carried out in patients with periorbital hyperpigmentation were found in the researched literature.

It is believed that dark eye circles and palpebral affections are more frequent in women and in individuals with darker skin, hair and eyes, regardless of their etiology. It affects all age groups, however it is more evident in older people.<sup>2-4</sup> After menopause, cutaneous collagen synthesis decreases 2.1% per year, and as the hypodermis becomes thinner, the skin's aesthetic condition worsens. The aging process also causes structural changes in the skin due to gravity and physiological alterations in the skin, which can be more intense when combined with actinic damage. When acting in an area that is low in collagen or subcutaneous tissue, or in areas with little muscular sustentation, gravity causes the skin to move downwards, becoming stretched and thinner, making the palpebral vessels more visible.<sup>2,6,14,16,25</sup>

Ohshima and colleagues studied palpebral skin and noticed that it is significantly less dense in patients with dark eye circles, which allows a clearer visualization of vessels and pigmentation due to the transparency of this area.<sup>7</sup>

### TOPICAL TREATMENTS

Periorbital hyperpigmentation is a common complaint in dermatology practices. However, it is rarely studied. Since it does not have a clearly defined etiopathogeny, there is no consensus regarding its treatment.

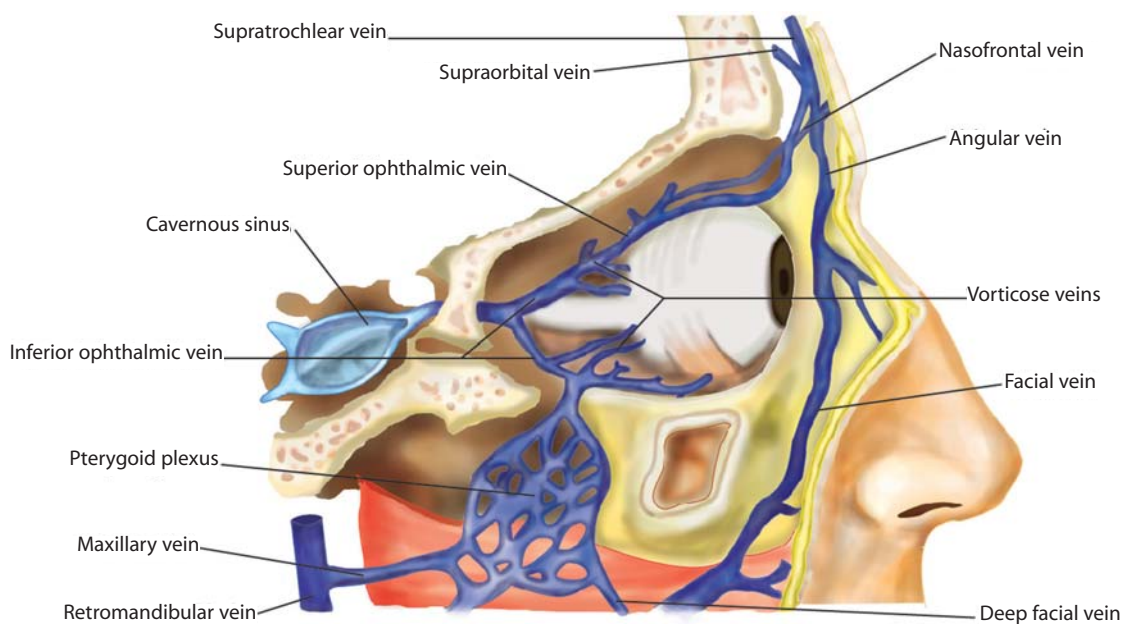


ILUSTRAÇÃO: PAULA PLUM

**Figure 2 - Eyelids' venous drainage**

Most topical treatments consist of the application of depigmenting products (vitamins C, E and K1; azelaic, phytic and kojic acids; arbutin; biosome C; magnesium ascorbyl phosphate; thioglycolic acid; hydroquinone; haloxyl). Nevertheless, there are few studies analyzing or comparing the efficacy of those medications or correlating the results with patients' epidemiological characteristics.<sup>2-4,25</sup>

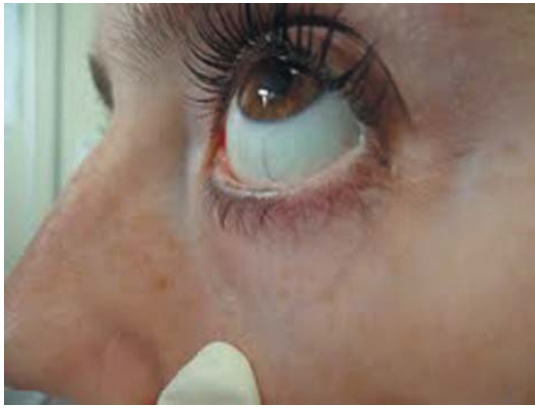An open, monocentric, non-paired clinical and non-randomized pilot study was recently published that demonstrated the efficacy and safety of treating infraorbicular pigmentation with 10% acid thioglycolic gel peeling. The study included 10 volunteers, aged 24-50, who underwent five sessions of peeling with 10% acid thioglycolic gel at 15-day intervals. The average clinical satisfaction rated by patients was 7.8; that of the applicator physician was 7.6; and that of the evaluator blunt physician was 6.8, with no statistically significant difference between them ( $p = 0.065$ ).<sup>3</sup> Thioglycolic acid, a depigmenter with an unpleasant scent, is suitable for hyperchromias with a predominantly vascular component, due to its capacity to absorb the hemoglobin's iron oxide, alleviating the dark eye circles.<sup>3,27</sup>

Ascorbic acid is a depigmenting agent that is less chemically stable in topical formulations. In addition to its whitening effect, it can also increase collagen synthesis, improving the skin's thickness, and in turn attenuate dark eye circles. Preference should be given to magnesium ascorbyl phosphate, a vitamin C derivative that is more stable and acts by inhibiting melanogenesis.<sup>28</sup> Ohshima and others conducted a clinical study to evaluate vitamin C's efficacy in treating dark eye circles. Volunteers ( $n = 14$ ) with lower eyelid hyperpigmentation were evaluated for six months, using a solution containing 10% sodium ascorbate on one side of the face and ascorbic acid glucoside on the other. The melanin and erythema indices, thickness and the inferior papillae dermis' echogenicity were evaluated bilaterally during the course of the study. The change in the erythema index was

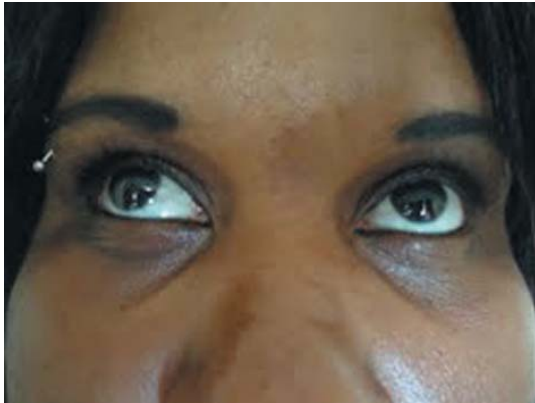significantly smaller on the side treated with sodium ascorbate compared to the side treated with the vehicle. The dermal thickness was greater on the side treated with sodium ascorbate compared to the other side, but the difference was not statistically significant. No significant differences were observed between the sides treated with ascorbic acid glucoside and those treated with the vehicle regarding the erythema index, echogenicity or dermal thickness. The authors concluded that sodium ascorbate can improve dark eye circles by increasing the lower eyelids' thickness and reducing the dark staining caused by the congestion of blood circulation.<sup>29</sup>

A study combining 2% phytonadione, 0.1% retinol, 0.1% vitamin C and 0.1% vitamin E in a gel, applied twice a day for eight weeks in 57 patients' lower eyelids, demonstrated that 27 (47%) presented reduced pigmentation; the procedure was considered by the authors to be very or moderately effective in the reduction of dark eye circles.<sup>6</sup>

Hydroquinone is a topical depigmenting agent that acts immediately by inhibiting the tyrosinase's activity. Secondly, and more slowly, it induces structural modifications in the membranes of the organelles of the melanocytes, accelerating the degradation of the melanosomes.<sup>7,14</sup> A combined study conducted with 18 patients who used 5% hydroquinone gel and 0.1% retinoic acid for six weeks, followed by the application of q-switched Ruby laser with the purpose of reducing epidermal and dermal pigmentation, respectively, showed excellent results that were confirmed by the patients' satisfaction level (considered excellent by 83.3%) and by the skin biopsies carried out before and after treatment (which demonstrated a decrease in dermal pigmentation in all patients).<sup>14</sup> There are several cosmetics containing hydroquinone in the market, however none of them was specifically formulated for the treatment of the eye area. The safety and efficacy of using those creams to treat hyperpigmentation in conditions other than melasma have not



**Figure 3 -** Periorbital hyperpigmentation of vascular pattern. Visualization of the vascularization under the skin when tractioning the inferior eyelid



**Figure 4 -** Predominantly melanic periorbital hyperpigmentation in phototype VI patient

yet been studied.<sup>30-32</sup>

Haloxyl is an anti-dark eye circles active substance that was shown to be effective in a study carried out in 22 patients who applied a gel containing 2% haloxidyl around one eye for 56 days. Participants were later evaluated by analyzing images using specialized software that gauged the shade of the dark circles. Haloxidyl is composed of chrysin, N-hydroxysuccinimide and matrikines – peptides liberated by extracellular matrix macromolecules' proteolysis. That medication's components seem to act synergically in the reduction of dark eye circles. Matrikines stimulate the synthesis of the extracellular matrix's components, reinforcing the palpebral tonus, while the chrysin and the N-hydroxysuccinimide act as bilirubin and iron chelators, respectively, reducing local pigmentation.<sup>33</sup>

Phytomenadione (phytokine) is synthetic vitamin K, which performs the same functions as natural vitamin K. It participates in the coagulation factors II, VII, IX and X synthesis, and acts as an essential cofactor in the post-transductional carboxylation of the precursors of the above mentioned coagulation factors. Vitamin K1 (0.5–2%) has been used topically to treat actinic purpura and traumatic purpura resulting from surgeries, and has been proven to help reduce the amount of extravascular blood and ecchymosis. As a result of its antihemorrhagic action, its use was also tested in the reduction of dark eye circles, however it was scientifically confirmed to cause allergic reactions, increased sensitivity and contact dermatitis at the site of application. It was subsequently forbidden by ANVISA (Brazilian General Agency of Cosmetics and Sanitary Surveillance), which prohibited the use of vitamin K in cosmetics.<sup>34,35</sup>

## LASER AND INTENSE PULSED LIGHT TREATMENTS

The use of intense pulsed light is recommended in the treatment of vascular dark eye circles due to its capacity to stimulate collagen synthesis and improve the skin's texture and color by selectively stimulating the temperature at the desired depth, without heating up the skin's surface.<sup>12</sup>

Intense pulsed light is more suitable for treating poikiloderma of Civatte, rosacea vascular lesions and solar melanoses, but can present good results in infraorbital hyperpigmentation after one to three sessions.<sup>12</sup>

West and Alster observed the whitening of the infraorbital skin after nine weeks of treatment with intense pulsed light, however the melanin spectrometry did not correlate with the results. Cymbalista described the clinical whitening of the lower eyelid's skin, and the maintenance of the results, without recurrence, after one year of treatment with intense pulsed light.<sup>8</sup>

Manuskiatti and others demonstrated that the combination of several laser types (CO<sub>2</sub>, Q-switched Alexandrite, Er:YAG and pulsed dye lasers) in a single session presented 75–100% positive results, with no reported complications.<sup>9</sup>

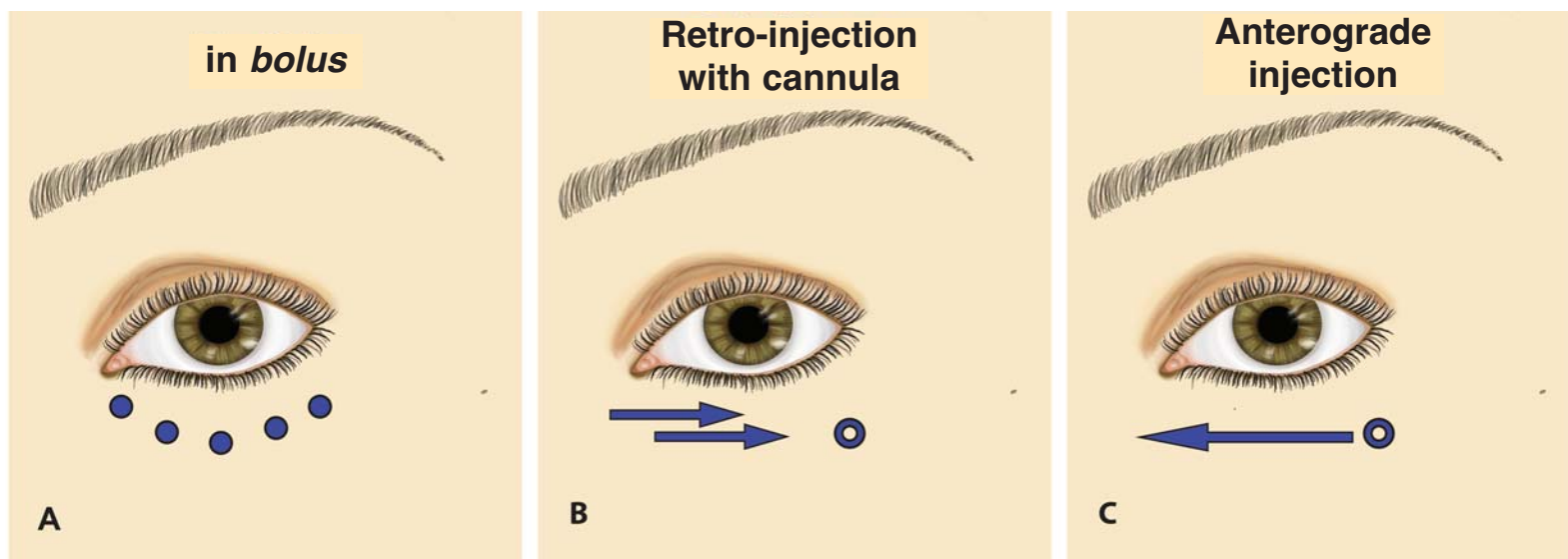
The combination of epidermal ablation with the CO<sub>2</sub> and Q-switched Alexandrite lasers presents better results than the use of the same lasers individually to treat dark eye circles. If the pigment is mainly originating in the epidermis, CO<sub>2</sub> removes it more efficiently, reaching a depth closer to the dermis, where Q-switched Alexandrite complements the therapy. The effects begin to appear six to eight weeks after the treatment.<sup>9</sup> The isolated use of CO<sub>2</sub> laser can also demonstrate good results, as in a study by West and Alster, carried out in a group of 12 patients, with a 50% improvement after nine weeks of treatment.<sup>10</sup>

The 694 nm q-switched Rubi laser has also demonstrated good results in the treatment of periorbital hyperpigmentation; Lowe and others<sup>36</sup> had 88.9% satisfactory responses in 17 patients and Watanabe and colleagues<sup>37</sup> had excellent results in two patients and good results in two of their other five patients.

Erbium laser can also be a good option for dark eye circles. With a 2,940 nm wavelength and water as its chromophore, it is recommended for some conditions in which there are constraints for the use of CO<sub>2</sub> laser. Erbium-YAG laser has weaker thermal and greater ablative effects; it can eliminate pigment without stimulating the formation of new pigment. Nonetheless, as its effects are superficial, deeper ablations (at the papillary dermis depth or deeper) cause bleeding. Whitening substances must be used for two or three months before the procedure to allow some reduction in pigmentation. The post-operative use of whitening substances and sunscreen is essential. Results have been definitive over three years of observation, without the long-term need to use whitening substances.<sup>38</sup>

## TREATMENTS WITH FILLERS

Another treatment recommended for dark eye circles is filling the nasojugal fold with hyaluronic acid. This substance is an essential component of the cellular matrix found in all tissues; it can retain water, to provide hydration and turgor to the



**Figure 5** - Palpebral filling application techniques: **A)** in bolus, **B)** retro-injection with cannula and **C)** Anteroinjection with cannula

skin. It is a polysaccharide with a gelatinous consistency, formed by several interlinked units of disaccharide containing glucuronic acid and N-acetyl glycosaminoglycan. It can be extracted from tissues or biosynthesized by bacteria through fermentation.<sup>12</sup>

When tractioning the malar region of some patients, a depression below the lower eyelid, medially towards the lachrymal duct, can be noticed. That is the area indicated for injecting hyaluronic acid. Better results are obtained in young patients, who have less skin and adipose tissue in that area. Based on experience and obtained results, it is suggested that the area is whitened with pulsed light sessions and the use of topical depigmenters at home in monthly intervals before the filling procedure. There are several application techniques. The main three are: *in bolus*; retro-injection with cannula and anterograde injection<sup>39-45</sup> (Figure 5).

1. *In bolus* technique (deep puncture): the area of application is marked in advance with small circles. The needle is then introduced at a 90° angle. When the deep supraperiosteal plane is reached, the needle must be retracted by 1 mm in order to avoid intravascular injection. Next, the product is injected *in bolus* in the site. The procedure is repeated in all marked circles. In order to avoid compromising the ocular lubrication, fillings are not carried out close to the lachrymal duct. Massage is recommended at the end of the procedure, in order to allow adequate modelling.<sup>39,44</sup>

2. Retro-injection with cannula technique: the filling region is marked with the shape of an ellipse and with a circle at the site of the anesthetic button. Next, an incision is made with a 27G needle, through which the 25x0.8 cannula (connected to the syringe containing the filling material) is introduced. A slight traction is applied in order for the supraperiosteal plane to be reached. The syringe is brought close to the entry orifice in order to inject the filler. If necessary, the procedure is repeated. The cannula is removed and the area is massaged.<sup>39</sup>

3. Anterograde injection technique (more common in Europe): the needle is introduced until it reaches the supraperiosteal plane, injecting the product at the same time.<sup>40,42,45</sup> It is believed that, since it is viscoelastic, as the product is injected it displaces important structures, avoiding intravascular injection.<sup>46,47</sup> It is important to apply a gentle massage after the procedure.

Goldberg and others described a technique in which several hyaluronic acid retro-injections are made in a fan-like shape in the infraorbicular plane, slightly above the periosteum (around 20-50 per side).<sup>41</sup> Kane<sup>39</sup> prefers the application of crossed retro-injections in two planes (deep and infraorbicular dermis, in a sandwich-like manner). Those two techniques have a greater likelihood of side effects, such as popular or string hypercorrections, ecchymoses, local hyper or hypopigmentation, ischemia due to intravascular injection, etc.<sup>39-45</sup>

Autologous fat transplants can also be a good alternative for dark eye circles; the increase in the subcutaneous fat vascularization and skin transparency in the periorbital region can be involved in its physiopathology.<sup>46</sup> A study by Pinski and colleagues (1992)<sup>47</sup> demonstrates good results for this procedure, which seems to be safe, however there is a controversy regarding the duration of the results.<sup>48,49</sup>

## CONCLUSION

Although dark eye circles are a constant complaint in dermatology practices, they do not yet have a clearly defined etiology or therapeutic method. Further studies on its etiology and epidemiology should be carried out, so that treatment alternatives can be developed for patients. ●

## REFERENCES

- Malakar S, Lahiri K, Banerjee U, Mondal S, Sarangi S. Periorbital melanosis is an extension of pigmentary demarcation line-F on face. *Indian J Dermatol Venereol Leprol*. 2007;73(5):323-5
- Steiner D. Clínica Denise Steiner [Internet]. Brasil SP. [date unknown]. Available from: [www.denisesteiner.com.br/derma\\_estetica/olheiras2.htm](http://www.denisesteiner.com.br/derma_estetica/olheiras2.htm)
- Costa A, Basile DVA, Medeiros VLS, Moisés AT, Ota S F, V CAJ. Peeling de gel de ácido tioglicólico 10% opção segura e eficiente na pigmentação infraorbicular constitucional. *Surgial & Cosmetic Dermatol* 2010;2(1):29-35.
- Freitag, FM e Cestari, TF: What causes dark circles under the eyes? *Journal of Cosmetic Dermatology* 2007; 6(3):211-5.
- Stefanato, CM e Bhawan, J. Diffuse hyperpigmentation of the skin: a clinicopathologic approach to diagnosis. *Semin Cutan Med Surg* 1997; 6(1):61-71.
- Mitsuishi T, Shimoda T, Mitsui Y, Kuriyama Y, Kawana S. The effects of topical application of phytonadione, retinol and vitamins C and E on infraorbital dark circles and wrinkles of the lower eyelids. *J Cosmet Dermatol*.2004; 3(2):73-5.
- Oshima, H e Takiwaki, H. Evaluation of dark circles of the lower eyelid: comparison between reflectance meters and image processing and involvement of dermal. *Skin Res Technol* 2008; 14(2):135-41.
- Cymbalista NC. Hiperchromia cutânea idiopática da região orbital: avaliação clínica, histopatológica e imunohistoquímica antes e após tratamento com luz intensa pulsada de alta energia. [tese] São Paulo(SP): Universidade de São Paulo; 2004.
- Manuskiatti W, Fitzpatrick RE, Goldman MP. Treatment of facial skin using combinations of CO2, Q-switched alexandrite, flashlamp-pumped pulsed dye, and Er:YAG lasers in the same treatment session. *Dermatol Surg* 2000; 26(2):725- 9.
- West TB, Alster TS. Improvement of infraorbital hyperpigmentation following carbon dioxide laser resurfacing. *Dermatol Surg*. 1998; 24(6):615-6.
- Momosawa, A et al. Combined Therapy Using Q-Switched Ruby Laser and Bleaching Treatment with Tretinoin and Hydroquinone for Periorbital Skin Hyperpigmentation in Asians. *Plast Reconstr Surg*. 2008; 121(1):282-8.
- Kede MPV, Sabatovich O. *Dermatologia Estética*. 2009; 17: 631-716.
- [author Unknown]. Md4arab [Internet]. [place unknown]. [date unknown]. Available from: <http://md4arab.com/main/articles/basic-medicine/37-Clinical-procedure/557-Eyelid-Anatomy.html>.
- Rosatelli-Neto JM. Posição do sulco palpebral superior [tese]. Ribeirão Preto: Faculdade de Medicina de Ribeirão Preto 1995;
- Paiva RS, Minaré-Filho AM, Cruz AA. Palpebral fissures changes in early childhood. *J Pediatr Ophthalmol Strabismus*. 2001;38(4):219-23.
- Lavker RM, Zheng PS, Dong G. Morphology and aged skin. *Clin Geriatr Med*. 1989; 5(1):53-67.
- Pitanguy I, Pamplona D, Weber HI, Leta F, Salgado F, Radwanski HN. Numerical modeling of facial aging. *Plast Reconstr Surg* 1998;102(1):200-204.
- Monteiro RLM. Revista Sinopse de Oftalmologia [Internet]. Brasil SP. [cited 2001 Jul]. Available from: [www.cibersaude.com.br/resvistas.asp?fase=r003&\\_materia=1596](http://www.cibersaude.com.br/resvistas.asp?fase=r003&_materia=1596).
- Van den Bosch WA, Leenders I, Mulder P. Topographic anatomy of the eyelids, and the effects of sex and age. *Br J Ophthalmol*. 1999;83(3):347-52.
- Richard LD, Wayne V, Adam WMM. *Grays – Anatomia para estudantes*; 2005.p.831.
- Alchorne MM, de Abreu MA. Dermatoses na pele negra. In: Rotta O. *Guia de dermatologia: clínica, cirúrgica e cosmética*. Barueri: Manole 2008; 593-608.
- Azulay, L. Melasma: do diagnóstico ao tratamento [Internet]. Brasil RJ. [date Unknown]. Available from: <http://www.cremerj.com.br/palestras/826.PDF>.
- Starkco RS, Pinkus S. Quantitative and qualitative data on the pigment cell of adult human epidermis. *J Invest. Dermatol*. 1957; 28:33-36.
- Goldschmidt H, Raymond JZ. Quantitative analysis of skin color from melanin content of superficial skin cells. *J Forensic Sci* 1972; 17(1):124-31.
- Melo FF. Consultório de Cirurgia Plástica Dr Francisco Falcão Melo [Internet]. Brasil RJ. [cited 2009 Jan 20]. Available from: <http://consultoriocirurgioplastica.blogs.sapo.pt/160202.html>
- Machado R. Melhor Amiga [Internet]. Brasil. [Unknown date]. Available from: <http://www.melhoramiga.com.br/2010/10/colirio-para-fins-esteticos-traz-riscos-a-saude>.
- [author unknown]. Natupele dermatocósmica [Internet]. Brasil. [date unknown]. Available from: [www.natupele.com.br/site.do?idArtigo=25](http://www.natupele.com.br/site.do?idArtigo=25)
- Nicoletti, MA., Orsine EM, Duarte, AC, Bueno, G.A.. Hiperchromias: Aspectos Gerais e Uso de Despigmmentantes Cutâneos. *Cosmetics & Toietries* 2002; 14(s.d.):46-51. Available from: [www.tecnopresseditora.com.br/pdf/NCT\\_443.pdf](http://www.tecnopresseditora.com.br/pdf/NCT_443.pdf).
- Ohshima H, Mizukoshi K, Oyobikawa M, Matsumoto K, Takiwaki H, Kanto H, Itoh M. Effects of vitamin C on dark circles of the lower eyelids: quantitative evaluation using image analysis and echogram. *Skin Res Technol* 2009; 15(2):214-217.
- Martins MA. Medicina NET [Internet]. Brasil SP. [date unknown]. Available from: [www.medicinanet.com.br/bula/5172/tri\\_luma.htm](http://www.medicinanet.com.br/bula/5172/tri_luma.htm)
- [author unknown]. Germed [Internet]. Brasil. [date unknown]. Available from: [http://www.germedpharma.com.br/site/uploads/tx\\_productspharma/082690\\_Hormoskin.pdf](http://www.germedpharma.com.br/site/uploads/tx_productspharma/082690_Hormoskin.pdf)
- [author unknown]. Medley [Internet]. Brasil SP. [cited 2011 April 12]. Available from: [www.medley.com.br/portal/bula/triderm\\_creme\\_15g.pdf](http://www.medley.com.br/portal/bula/triderm_creme_15g.pdf)
- [author unknown]. Mapric®- Haloxyl: Informativo institucional Farmatec [Internet]. Brasil SP. [date unknown]. Available from: [www.mapric.com.br/anexos/boletim465\\_14112007\\_081118.pdf](http://www.mapric.com.br/anexos/boletim465_14112007_081118.pdf).
- [author Unknown]. Mapric [Internet]. Brasil SP. [date unknown]. Available from: [http://www.mapric.com.br/anexos/boletim\\_562\\_10122007\\_105123.pdf](http://www.mapric.com.br/anexos/boletim_562_10122007_105123.pdf)
- Agência Nacional de Vigilância Sanitária. ANVISA [Internet]. Brasil. [date Unknown]. Available from: [http://portal.anvisa.gov.br/wps/portal/anvisa/educacao/!ut/p/c4/04\\_SB8K8xLLM9MSSzPy8xBz9CP0os3hnd0cPE3](http://portal.anvisa.gov.br/wps/portal/anvisa/educacao/!ut/p/c4/04_SB8K8xLLM9MSSzPy8xBz9CP0os3hnd0cPE3)
- Lowe NJ, Wieder JM, Shorr N, et al. Infraorbital pigmented skin. Preliminary observations of laser therapy. *Dermatol Surg* 1995; 21:767-770.
- Watanabe S, Nakai K, Ohnishi T. Condition known as dark rings under the eyes in the japanise population is a kind of dermal melanocytosis which can be successfully treated by Q-switched ruby laser. *Dermatol Surg* 2006; 32:785-789.
- Kede MPV, Sabatovich O. *Dermatologia estética* 2009; 19.4: 801-811.
- Kane MA. Treatment of tear trough deformity and lower lid bowing with injectable hyaluronic acid. *Aesth Plast Surg* 2005; 29:363-367.
- Matarasso SL, Carruthers JD, Jewell ML; Restylane Consensus Group. Consensus recommendations for soft-tissue augmentation with nonanimal stabilized hyaluronic acid (Restylane). *Plas Surg* 2006; 117 (3):3s-34s.
- Goldberg RA, Fiaschetti D. Filling the periorbital hollows with acid gel: initial experience with 244 injections. *Ophthal Plast Reconstr Surg* 2006; 22(5): 335-41; discussion 341-343.
- Carruthers A, Carruthers JD. Non-animal-based hyaluronic acid fillers: scientific and technical considerations. *Plast Reconstr Surg* 2007; 120(suppl 5): 33s-40s.
- Rohrich R, Ghavami A, Crosby M. The role of hyaluronic acid fillers (Restylane) in facial cosmetic surgery: review and technical considerations. *Plast Reconstr Surg* 2007; 120(suppl 6): 41s-54s.
- Steinsapir KD, Steinsapir SM. Deep-fill hyaluronic acid for the temporary treatment of the naso-jugal groove: a report of 303 consecutive treatments. *Ophthal Plast Reconstr Surg* 2006; 22(5): 344-348.
- Bosniak S, Sadick NS, Cantisano-Zilkha M et al. The hyaluronic acid push technique for the nasojugal groove. *Dermatol Surg* 2008; 34(1): 127-131.
- Marcussi S. Segredos em medicina estética. 2008; 9: 101-143.
- Roh MR, Chung KY. Infraorbital Dark Circles: Definition, causes, and treatment options. *Dermatol Surg* 2009; 35:1163-1171.
- Pinski KS, Roenigk HH jr. Autologous fat transplantation. Long-term follow-up. *J Dermatol Surg Oncol* 1992; 18:179-184.
- Fagrell D, Eneestrom S, Berggren A, et al. Fat cylinder transplantation: an experimental comparative study of three different kinds of fat transplants. *Plast Reconstr Surg* 1996; 98:90-96; discussion 97-98. *Plast reconstr Surg*. 2003; 112(5 suppl):665-725.